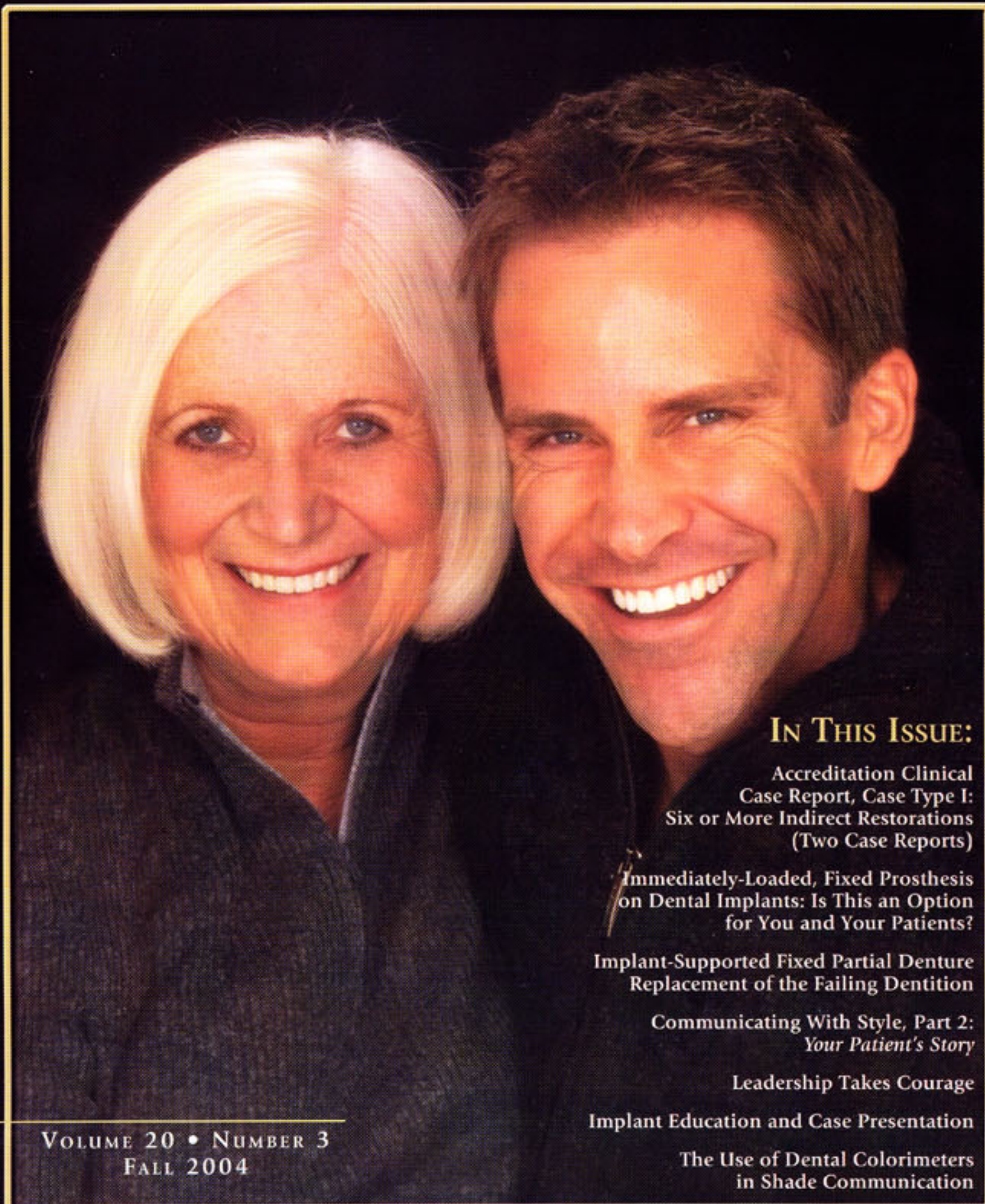


The JOURNAL of Cosmetic Dentistry

The Official Journal of the American Academy of Cosmetic Dentistry®



VOLUME 20 • NUMBER 3
FALL 2004

IN THIS ISSUE:

Accreditation Clinical
Case Report, Case Type I:
Six or More Indirect Restorations
(Two Case Reports)

Immediately-Loaded, Fixed Prosthesis
on Dental Implants: Is This an Option
for You and Your Patients?

Implant-Supported Fixed Partial Denture
Replacement of the Failing Dentition

Communicating With Style, Part 2:
Your Patient's Story

Leadership Takes Courage


Implant Education and Case Presentation

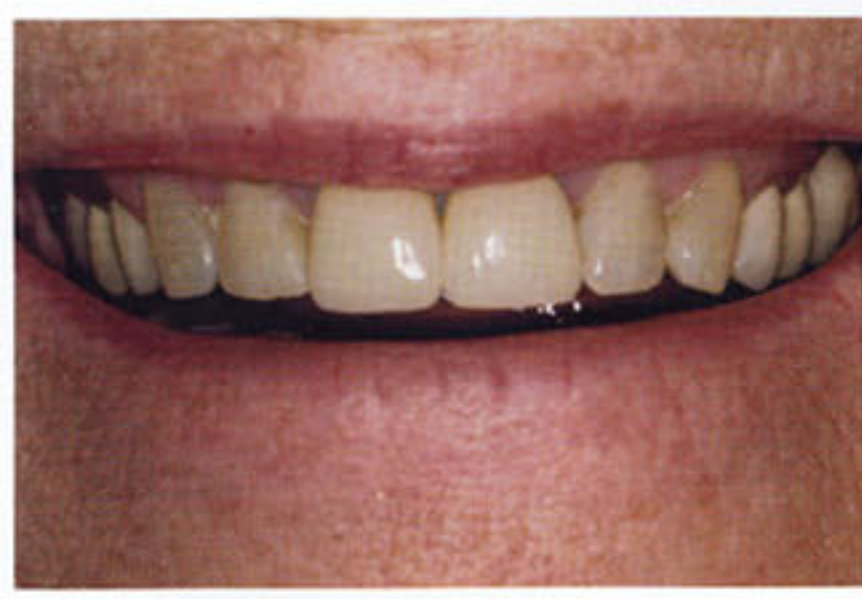The Use of Dental Colorimeters
in Shade Communication

ABOUT THE COVER

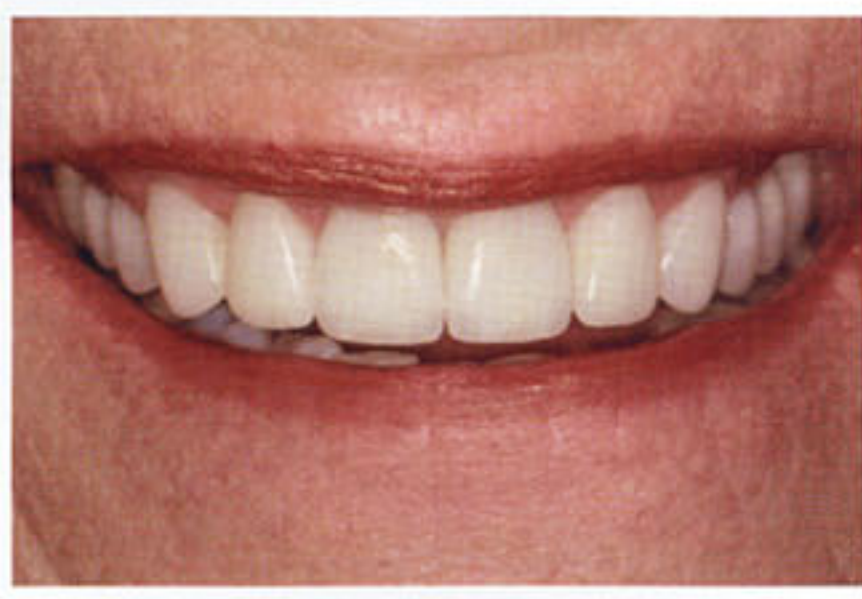This 62-year-old woman's main concern was that her dark crowns made her feel "old." She wanted to rejuvenate her smile so that she could look as young as she felt! After completing a comprehensive examination, I had a Master Diagnostic Model® (Valley Dental Arts; Stillwater, MN) fabricated according to the proposed changes that we wanted in the design of her new smile. We chose Authentic® porcelain (Microstar; Lawrenceville, GA) for the restorations because it allowed us to use the same porcelain for the veneers and crowns as well as the press-to-metal bridge (## 13-15). The veneers and all porcelain crowns were cemented with Insure luting resin (Cosmedent; Chicago, IL), and the bridge was cemented with RelyX™ Unicem (3M ESPE; St. Paul, MN). Her lower teeth were whitened with Opalescence® (Ultradent; South Jordan, UT) home-bleaching system for two weeks. The end result gave her a bright beautiful smile and a more youthful appearance.

Her 39-year-old son was unhappy with the discoloration of his teeth and the amalgam restorations present in many of his posterior teeth. We removed the amalgam and replaced the restorations with Filtek™ Supreme direct-bonded composites (3M ESPE). His teeth were bleached with Nite White® (Discus Dental; Culver City, CA) for approximately three weeks. Now both he and his mother have something to smile about!

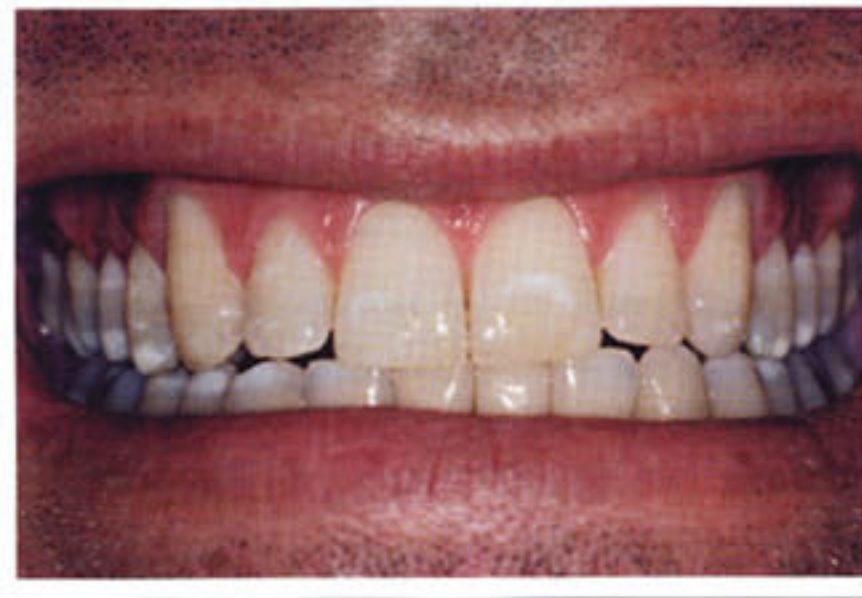Esthetic dentistry by Nancy Norling, D.D.S., Minneapolis, MN. Esthetic ceramic artistry by Jenny Wohlberg, Valley Dental Arts, Stillwater, MN. Photography by Charles Krusac, Minneapolis, MN. 



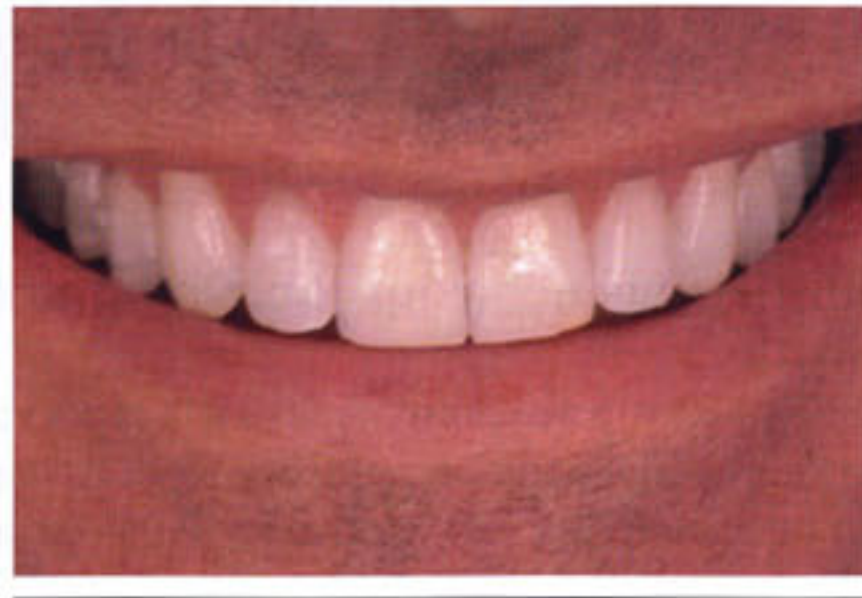Before



After



Before



After

